

LETTER TO THE EDITOR

Fat removal using a new cryolipolysis device: a retrospective study of 418 procedures

Editor

The selective effect of cold on the hypodermis is a well-known medical phenomenon.^{1,2} Cryolipolysis³ induces selective apoptosis of the adipocytes using controlled exposure to intense cold. Its safety and efficacy has been reported in several studies^{4,5} but was recently challenged.⁶

A retrospective, observational, monocentric post-marketing study was conducted. A single session of cryolipolysis was evaluated on subjects who consulted for fat removal. Subjects were included consecutively and paid for their treatment. Patients

with medical history of cold disorders such as cryoglobulin or Raynaud's disease, visceral hernias, pregnancy, caesarean section within the last 6 months were excluded. The device used [Cristal™ cryolipolysis (Deleo, Saint Raphael, France)] benefits from the medical CE marking. It has two slightly curved handpieces that can be used simultaneously, with three different sizes. Thick protective epidermal membrane soaked with a cold-resistant gel was applied on the area. Cooling temperature was between -6°C and -10°C . Treatment duration was 60 min per area. A 5-min energetic massage was carried out immediately after treatment. A topical cream containing arnica extract (Cicabio Arnica+®, Laboratoire Bioderma, Lyon, France) which reduces bruising was prescribed in order to limit and treat secondary ecchymosis caused by suction.

A total of 418 areas in 147 subjects underwent the procedure. Areas were: abdomen (144), anterolateral flank (156), inner thighs (48), back (26), underside of buttocks (26), inner knees

Table 1 Treatment outcome

| Efficacy | Location | N (patients) | Number of probes placed | Mean | Standard deviation | Minimum | Maximum | Median |
|------------------------------|-----------------------|--------------|---|--------|--------------------|---------|---------|--------|
| Loss of perimeter (cm) | Abdomen | 24 | 1 | 2.38* | 1.69 | 0 | 6 | 2 |
| | Thighs | 3 | 1 | 1.33 | 0.58 | 1 | 2 | 1 |
| | Knees | 3 | 1 | 2.00 | 1.73 | 1 | 4 | 1 |
| | Both flanks | 8 | 2 | 2.13† | 2.36 | 0 | 7 | 2 |
| | Under the Breasts | 2 | 2 | 3.00 | 1.41 | 2 | 4 | 3 |
| | Buttocks | 2 | 2 | 4.50 | 4.95 | 1 | 8 | 4.5 |
| | Both flanks + abdomen | 15 | 3 | 4.00*† | 2.36 | 2 | 10 | 3 |
| Total loss of perimeter (cm) | | 57 | – | 2.79 | 2.15 | 0 | 10 | 2 |
| Desire for a second session | | 57 | Yes: 45 (80.36%) No: 11 (19.84%) Not specified: 1 (1.75%) | | | | | |

*CI at 95% for the difference in means: (0.173; 3.077).

†t-test of the difference in means = 0 (and ≠): T-value = 2.32; P-value = 0.030; DL = 22.

†CI at 95% for the difference in means: (–0.34; 4.09).

t-test of the difference in means = 0 (and ≠): T-value = 1.82; P-value = 0.091; DL = 14.

| Tolerance | Number of side-effects | Percentages per subject (%) (n = 147) | Percentages per area treated (%) (n = 418) |
|--|------------------------|--|---|
| Pain making treatment impossible | 1 | 0.68 | 0.24 |
| Vasovagal attack | 3 | 1.36 | 0.48 |
| Painful induration after the session | 4 | 2.72 | 0.96 |
| Skin anaesthesia in the treatment area | 1 | 0.68 | 0.24 |
| Large bruising | 2 | 1.36 | 0.48 |
| Erythema and blistering | 1 | 0.68 | 0.24 |
| Total | 12 | 7.48 | 2.63 |

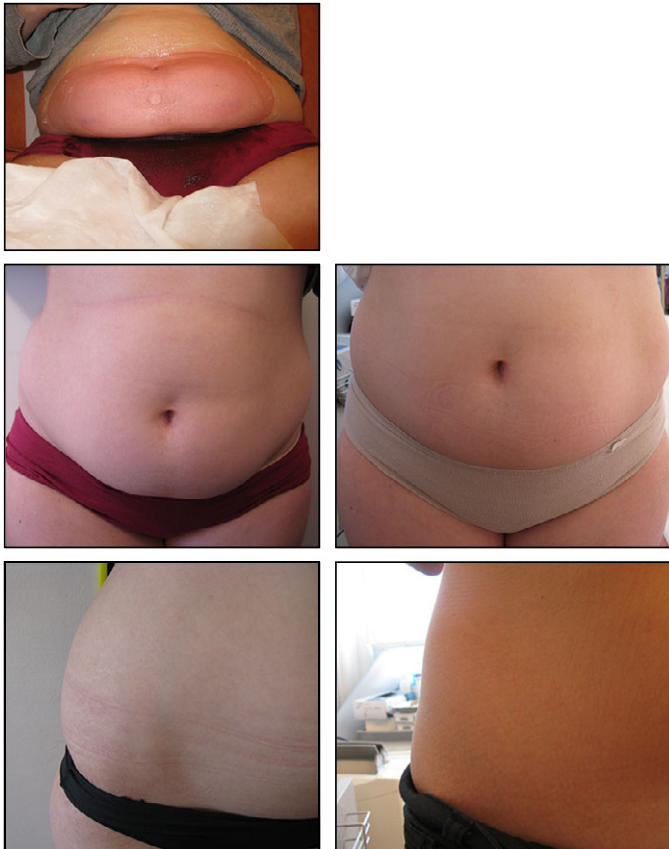


Figure 1 Up: just after treatment, down before (left) and 2 months after treatment (right)

(12) and breasts (6). One hundred and thirty-six (92.5%) subjects did not experience any adverse events. Two procedures could not be performed: one because of pain caused by lipedema,⁷ the second because of a vasovagal attack with loss of consciousness 20 min after the probe was placed. Ten other subjects experienced unusual adverse events: vasovagal symptoms without loss of consciousness that did not interfere with treatment, painful induration after the session, skin anaesthesia in the treatment area, large bruising, erythema and blistering (Table 1). No serious or irreversible complication was reported.

Data from 57 area treated were reviewed for efficacy (Table 1, Fig 1). A statistically significant mean loss of circumference of 2.8 cm ($P < 0.05$) was observed after the procedure including 1–3 handpieces. A loss of circumference of at least 1 cm was observed in 89.4% of patients; the maximum loss observed was 10 cm. A total of 75.4% of the patients were satisfied or very satisfied and 80.6% expressed their desire to make for a second session. It was a positive correlation between the subject's satisfaction and the objective decrease in circumference. There was no correlation between the subject's age or initial perimeter and the relative or absolute loss of circumference.

Our study allowed, evaluating objectively, the safety and efficacy of a new cryolipolysis device on a high number of

areas treated. The majority of adverse events observed were already reported.⁴ One incidence of cold burning was reported. This was a superficial burn – erythema and blistering which healed rapidly. This incidence was caused by a membrane slipping and not because of the device malfunctioning. Overall, the frequency of this incidence (0.24%) was much lower than that for other energy-based devices, such as hair removal lasers or radio frequency.⁴ No paradoxical adipose hyperplasia, considered being a much more serious adverse event, was reported.⁸

We made evaluations as objective as possible using anatomical markings and taking multiple measurements. The objective effect and level of subject satisfaction was very high. Since all subjects paid for their treatment, there was no gratitude bias.⁹ Unfortunately, we failed in searching criteria statistically correlated with good answer to the procedure; age and initial parameters did not seem to influence treatment success.

Our study confirmed that the new cryolipolysis device CristalTM is safe and effective to remove fat.

M. Naouri^{1,2,*}

¹Centre Laser, Nogent sur Marne, France, ²Centre Laser International de la Peau, Paris, France

*Correspondence: M. Naouri. E-mail: michaelnaouri@yahoo.fr

References

- 1 Vickers R. Equestrian cold panniculitis. *Br Med J* 1981; **282**: 405–431.
- 2 Epstein EH, Oren ME. Popsicle panniculitis. *N Engl J Med* 1970; **282**: 966–967.
- 3 Avram MM, Harry RS. Cryolipolysis for subcutaneous fat layer reduction. *Lasers Surg Med* 2009; **41**: 703–708.
- 4 Dierickx CC, Mazer JM, Sand M, Koenig S, Arigon V. Safety, tolerance, and patient satisfaction with noninvasive cryolipolysis. *Dermatol Surg* 2013; **39**: 1209–1216.
- 5 Mulholland RS, Paul MD, Chalfoun C. Noninvasive body contouring with radiofrequency, ultrasound, cryolipolysis, and low-level laser therapy. *Clin Plast Surg* 2011; **38**: 503–520.
- 6 Tremaine M, Avram MM. FDA MAUDE data on complications with lasers, light sources, and energy-based devices. *Lasers Surg Med* 2015; **47**: 133–140.
- 7 Naouri M, Samimi M, Atlan M *et al.* High-resolution cutaneous ultrasonography to differentiate lipoedema from lymphoedema. *Br J Dermatol* 2010; **163**: 296–301.
- 8 Singh SM, Geddes ERC, Boutrous SG, Galiano RD, Friedman PM. Paradoxical adipose hyperplasia secondary to cryolipolysis: an underreported entity? *Lasers Surg Med* 2015; **47**: 476–478.
- 9 Shek SY, Chan NPY, Chan HH. Non-invasive cryolipolysis for body contouring in Chinese—a first commercial experience. *Lasers Surg Med* 2012; **44**: 125–130.

DOI: 10.1111/jdv.13899
